Clin Oral Invest
DOI 10.1007/s00784-013-1011-6

SHORT COMMUNICATION

Number of accessory or nutrient canals in the human mandible

Johan K. M. Aps

Received: 14 May 2013 / Accepted: 24 May 2013

Abstract
Objectives The aim of the study was to assess the presence, location and the number of accessory or nutrient canals in the body of the mandible by means of cone beam CT images, obtained with the Planmeca ProMax® 3D Max device.
Material and methods Seventy-four cone beam images of the mandible from adult patients (37 males and 37 females) who were imaged for dental implantology planning or third molar extraction were used to assess the number and location of accessory or nutrient canals. All images were taken with the same machine (Planmeca® ProMax 3D Max) at 200-, 400- or 600-μm resolution. Distinction was made between canals entering or exiting the mandible superior or inferior of the inferior alveolar canal and between similar canals superior or inferior of the genial tubercula.
Results The number of accessory canals varied between nil to 11. No statistical significant difference between males and females was found with regard to the number or location of accessory canals in the mandible. Only 5.4 % of patients had no accessory canals. One to five accessory canals were found in 71.6 %, and 23 % of patients had more than five accessory canals. The majority (81 %) of patients had between two and six accessory canals.
Conclusion It seems that subjects showing no accessory canals whatsoever should be considered exceptional as more subjects with than without accessory canals in the body of the mandible were found.
Clinical relevance These results are clinically relevant for mandibular surgery and mandibular local anaesthesia.

Keywords Nutrient canals · Accessory canals · Mandible · Cone beam CT

J. K. M. Aps (✉)
The Center for Pediatric Dentistry, Department of Pediatric Dentistry, University of Washington, Magnuson Park, Building 25 – 6222 NE 74th Street, Seattle, WA 98115, USA
e-mail: apsj@uw.edu

Introduction

It can be stated that two reports by Nortjé et al. in 1977, where the anatomy of the inferior alveolar nerve path was described based on panoramic radiographs, have lead most clinicians for a long time [1, 2]. A substantial part of the literature has been focusing on the mandibular nerve canal and the mental foramen [3–23]. Panoramic images do not allow for buccal or lingual accessory canals to be diagnosed, while accessory foramina and their content in the body of the mandible are held responsible for problems in achieving efficient mandibular nerve block anaesthesia, for intra-operative and post-operative complications when oral surgery, such as implant placement and third molar extractions, are performed. Cone beam computed tomography (CBCT), multislice computed tomography and magnetic resonance imaging are able to show these canals better [24–38]. Literature is not consistent in the terminology of nutrient and accessory canals, but both canals actually have the same radiological and anatomical appearance, namely a canal through either the buccal or the lingual cortical plate [39]. Thanks to the availability of CBCT in dentistry, these canals can be detected easily and the information can be used to guide the clinician to perform presurgical planning for implantology and extractions of impacted teeth [40].

The radiographical image may provide good anatomical information for the clinicians regarding the location of the inferior alveolar nerve, the mental foramen and other important anatomical landmarks in the mandible. However, little is published on the number of accessory or nutrient canals in the body of the mandible. The present study focused at the latter and may be explaining why some patients still experience pain during cavity preparations, implant placement and impacted tooth removal.

Aim

The aim of the present study was to assess the presence and the number of so-called accessory or nutrient canals entering the

Published online: 07 June 2013

buccal or lingual cortical plates of the mandible, by means of a retrospective study of cone beam CT images of the mandible.

Material and methods

A total of 74 cone beam images (37 males and 37 females) of mandibles were ad randomly chosen from the Ghent University Dental School outpatient clinic Planmeca ProMax 3D Max Romexis® database, where the author was working at the time. The patients' details were reduced to birthday and sex. Ethnical background and other personal details were not collected from the database. These CBCT images were all taken for diagnostic purposes (e.g. implant planning and impacted third molar extraction planning) and all concerned dentulous adult patients (>18 years old) without medically compromising conditions.

Spatial resolution of the CBCT images was either 200, 400 or 600 μm, depending of the indication. The field of view was either (diameter × height) 100 mm × 55 mm or 100 mm × 90 mm or 100 mm × 130 mm, depending on the indication. The manufacturer's preferred exposure settings were unchanged.

Accessory or nutrient canals were defined as radiolucent canals running through the buccal and/or lingual cortical plate of the mandible into the trabecular bone [39].

The investigator was a trained dental and maxillofacial radiologist and was used to work with the Romexis® software tools. All images were viewed under the same ambient light conditions (a faint light from the ceiling) on the same monitor (Sony Bravia 40-in. monitor), with the investigator at 90° in front of the screen. Short 5-min breaks were allowed after every five cases, during which the investigator did not leave the room. The investigator was calibrated before on 20 CBCT datasets. All 20 cases were assessed for accessory canals twice with 2 weeks in between. Both results were assessed and an intra-examiner agreement of 90 % was found. Contrast and brightness were adjusted for each image and transverse sectioning through the mandible was always performed in 1-mm steps or less. The images were always viewed in the same order, namely from posterior to anterior and back. The latter was performed in all three orthogonal planes (axial, coronal and sagittal).

In order to obtain an idea of where the so-called accessory canals were more apparent, the mandible was divided into two posterior and one anterior sectors. The posterior sectors were defined as posterior of the mental foramen, while the anterior sector was defined as the region between the two mental foramina. Each sector was subdivided into a superior and inferior part. For the posterior sector, this subdivision was defined as superior or inferior of the inferior alveolar nerve canal. For the anterior sector, the subdivision was defined as superior or inferior of the tubercula geniculata or spina mentalis.

All results were immediately put in an Excel digital database, which was subsequently diverted into a MedCalc® file (MedCalc® medical statistical software, Mariakerke, Belgium) for appropriate descriptive and statistical analysis.

Results

In Table 1, the distribution of the number of canals in every sector and for both sexes can be found. No statistical significant difference in the number of accessory canals was observed between sexes, nor between left and right sides of the mandible.

The frequency of the number of patients with zero to 11 accessory canals can be observed in Table 2. Only 5.4 % of

Table 1 Number of accessory canals found per sector in the mandible, per sex and for the total sample

	Male (*N*=37) Range of number of canals	Female (*N*=37) Range of number of canals	All patients (*N*=74) Range of number of canals
Accessory inferior of left IAN	0–3	0–2	0–3
Accessory superior of left IAN	0–2	0–1	0–2
Accessory on the left	0–3	0–2	0–3
Accessory inferior of right IAN	0–3	0–3	0–3
Accessory superior of right IAN	0–1	0–1	0–1
Accessory on the right	0–4	0–3	0–4
Accessory inferior of genial tubercula	0–3	0–5	0–5
Accessory superior of genial tubercula	0–5	0–3	0–5
Accessory near genial tubercula	0–8	0–6	0–8
Total number of accessory canals	0–11	0–7	0–11

IAN inferior alveolar nerve

Table 2 Frequency table of the number of patients per number of accessory canals observed on cone beam CT in the entire body of the mandible

Number of canals	0	1	2	3	4	5	6	7	8	9	10	11
Number of patients	4	3	16	14	10	10	10	5	0	1	0	1

the subjects had no accessory canals, 4 % had only one, while 81 % had two to six accessory canals. About 23 % of the subjects had more than five accessory canals. One individual had 11 accessory canals.

In Table 3, the number of images per resolution type can be found. It is clear that the majority of the images was taken at 200-μm resolution. At this resolution, no statistical significant difference in the mean number of accessory canals between sexes was found. Only for the 400-μm resolution images, a statistical significant difference in the number of accessory canals could be observed between males and females (P=0.0166). Females had a mean number of canals of 4.6 while males only showed a mean of 1.7. When comparing the mean number of accessory canals per resolution setting, a statistical significant difference (P=0.0087) was observed between 200 and 600 μm. More than double the number of accessory canals could be detected at 200 μm than at 600 μm. The latter should be interpreted with care as the number of examinations at both resolutions is very different. When not taking the resolution of the images into account, the mean number of accessory canals was 3.8 and no statistical significant difference could be found between both sexes.

Table 4 shows the range and mean number of canals per region with regard to spatial resolution. Only between 200- and 600-μm spatial resolution, a statistical significant difference was noticed in the number of canals, with respect to accessory canals superior (P=0.036) or inferior (P=0.042) of the genial tubercula. No other significant differences in the number of canals could be found between 200-, 400- or 600-μm resolution images.

Figure 1 shows some examples of accessory or nutrient canals as observed on the CBCT images, with spatial resolution varying between 200 and 600 μm. From this figure, it becomes clear that at 200-μm resolution, a better distinction can be made of these accessory canals than at 600-μm resolution images.

Discussion

The results of this study are an important addendum to the already published literature on neurovascular anatomy of the human mandible and the numerous papers on the nutrition canals in the symphysis area of the mandible [2–23, 36, 41–45]. Although the present study could not identify the nature of the neurovascular content of the observed canals, it clearly illustrates the possible contents mentioned in earlier literature: the nerve to the mylohyoid, the lingual nerve, an additional branch of the inferior alveolar nerve, the long buccal nerve and the auriculo-temporal nerve have been named as responsible branches of the trigeminal nerve that are responsible for the sensibility of mandibular teeth. Besides these, the first cervical nerve, the facial nerve, the hypoglossal nerve and the glossopharyngeal nerve have also been named in this respect [41–44, 49]. Knowing this, it can be understood that a traditional inferior alveolar nerve block or even an altered technique like a Gow-Gates or Vazirani-Akinosi block, where the mandibular nerve is approached closer to the foramen ovale in an attempt to anaesthetize more branches of that nerve, will not be 100 % sufficient if the above-mentioned nerve branches are connected with teeth [37, 38, 47–53].

Alternatives to injections, electro-analgesia and electro-acupuncture, have been explored, but it has proven not to be as efficient as a local anaesthetic [54, 55]. Very peculiar is the experience that during excavating a carious lesion, one particular spot in the tooth's cavity gives the patient an acute excruciating pain caused by a tactile stimulus. The latter sounds

Table 3 Resolution of the CBCT images in relation to the number of accessory canals, per sex and for the total of images

Resolution (μm)	N males	Mean number of accessory canals	N females	Mean number of accessory canals	N total	Mean number of accessory canals
200	26	4.2	30	4.2	56	4.2**
400	6	1.7*	5	4.6*	11	3.0
600	5	1.8	2	2.5	7	2.0**
200/400/600	37	3.5	37	4.2	74	3.8

*P=0.0166; **P=0.0087, statistical significant difference during T tests

Table 4 The range and mean number of canals in the body of the mandible per topography and per spatial resolution of cone beam CT scans

	200-μm Resolution range [mean]	400-μm Resolution range [mean]	600-μm Resolution range [mean]
Accessory inferior of left IAN	0–3 [0.54]	0–1 [0.45]	0–1 [0.14]
Accessory superior of left IAN	0–2 [0.25]	0–1 [0.09]	0–1 [0.14]
Accessory inferior of right IAN	0–3 [0.52]	0–1 [0.45]	0–1 [0.14]
Accessory superior of right IAN	0–1 [0.14]	0–1 [0.27]	0
Accessory inferior of genial tubercula	0–5 [1.25]**	0–3 [1.00]	0–1 [0.71]**
Accessory superior of genial tubercula	0–5 [1.25]*	0–2 [0.73]	0–1 [0.86]*
Total number of accessory canals	0–11 [4.20]	0–7 [3.00]	0–3 [2.00]

IAN inferior alveolar nerve

*P=0.036; **P=0.042; statistical significant difference during T tests

familiar to many dental professionals. This leads in many cases to painful instead of painless dentistry, as several attempts to anaesthetize the tooth often fail. The use of intra-osseous, osteocentral and also called transcortical anaesthesia techniques may solve the problem of these accessory canals supplying nerve branches to the mandibular teeth [44, 46]. A local anaesthetic injected into the spongy bone, where the nerve branches run through, will eventfully anaesthetize the tooth, whatever the origin of the nerve branch being responsible for innervating the tooth.

In the clinic, some patients may also experience pain during implant placement. Again, the nutrient canals can be held responsible for this. The same holds for post-operative bleeding of pain after surgical procedures, such as implant placement and impacted tooth extraction. Nutrient canals or accessory canals can hold a nerve and a blood vessel, which can explain the complications. The presence of accessory canals is often overlooked by implantologists and they should be pointed out to them by dental and maxillofacial radiologists when reading the images.

The results of the present study show clearly that patients without accessory or nutrient canals are exceptional. Only 5.4 % of the investigated individuals had no accessory canals whatsoever. It seems therefore more correct to speak of exceptions if patients have no accessory or nutrient canals in their mandible. Assessing the presence of accessory canals in the mandible is important and should not be ignored.

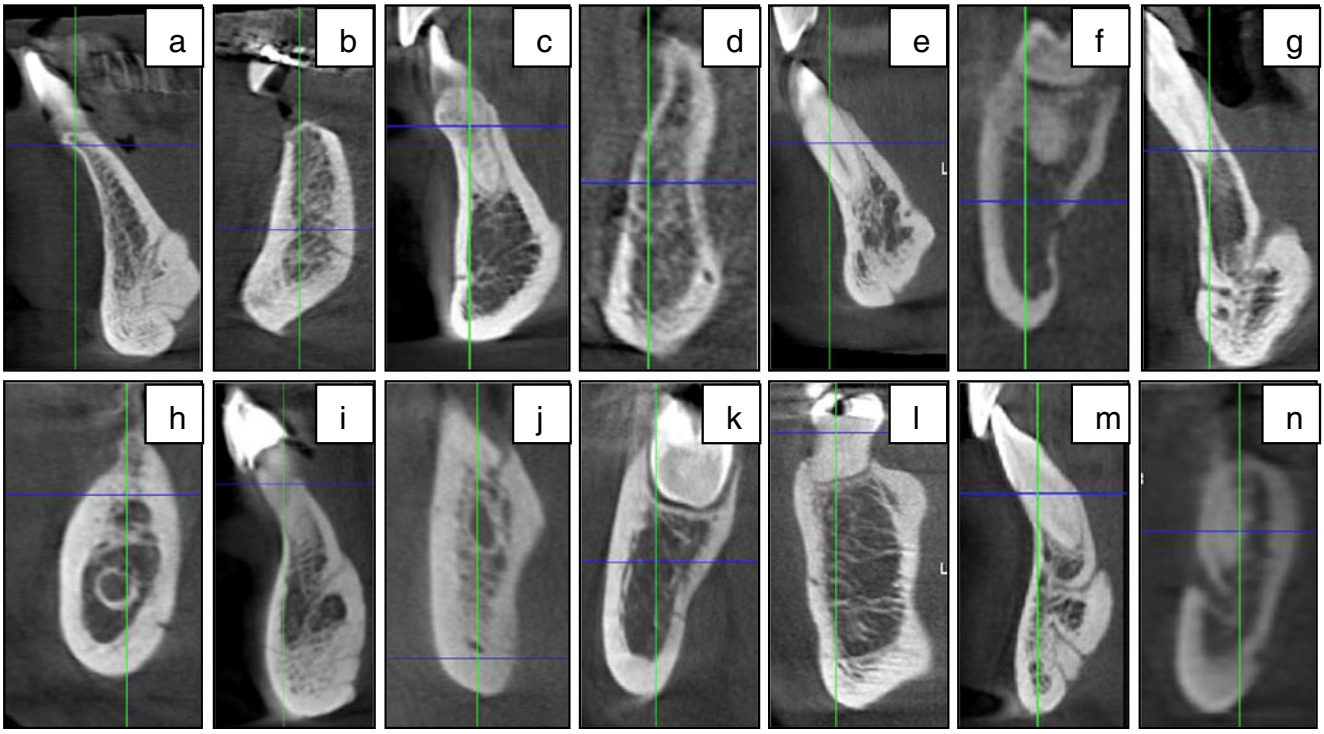

Fig. 1 Examples of CBCT images with identifiable accessory canals (all images are at 200-μm resolution except for **d** and **j** that are at 400-μm resolution, and for **f** and **n** that are at 600-μm resolution)

Conclusion

Patients without so-called accessory canals in the mandible are to be called exceptional, as only 5.4 % of the studied subjects had no accessory canals whatsoever from this present study. In other words, with regard to the results of this study, accessory canals should be considered as "natural and normal", as about 95 % of subjects exhibited between one and 11 accessory canals. These canals probably contain nerve branches, based on literature, originating either from the nerve to the mylohyoid, the lingual nerve, the long buccal nerve, an extra inferior alveolar nerve, the auriculo-temporal nerve, the facial nerve, the hypoglossal nerve, the glossopharyngeal nerve and the first cervical nerve.

Conflict of interest The author declares that there is no conflict of interest.

References

1. Nortjé CJ, Farman AG, Grotepas FW (1977) Variations in the normal anatomy of the inferior dental (mandibular) canal: a retrospective study of panoramic radiographs from 3612 routine dental patients. Br J Oral Surg 15:55–63
2. Nortjé CJ, Farman AG, Joubert JJ (1977) The radiographic appearance of the inferior dental canal: an additional variation. Br J Oral Surg 15:171–172
3. Claeys V, Wackens G (2005) Bifid mandibular canal: literature review and case report. Dentomaxillofac Rad 34:55–58
4. Miloglu O, Yilmaz AB, Caglayan F (2009) Bilateral bifid mandibular canal: a case report. Med Oral Patol Oral Cir Bucal 5:E244–E246
5. Kuribayashi A, Watanabe H, Imaizumi A, Tantanapornkul W, Katakami K, Kurabayashi T (2010) Bifid mandibular canals: cone beam computed tomography evaluation. Dentomaxillofac Rad 39:235–239
6. Naitoh M, Yoshida K, Nakahara K, Gotoh K, Ariji E (2011) Demonstration of the accessory mental foramen using rotational panoramic radiography compared with cone beam computed tomography. Clin Oral Impl Res 22:1415–1419
7. Kalender A, Orhan K, Aksoy U (2012) Evaluation of the mental foramen and accessory mental foramen in Turkish patients using cone-beam computed tomography images reconstructed from a volumetric rendering program. Clin Anat 25:584–592
8. Haknatir A, Ilgaz K, Turhan-Haknatir N (2010) Evaluation of mental foramina in adult living crania with MDCT. Surg Radiol Anat 32:351–356
9. Thakur G, Thomas S, Thayil SC, Nair P (2011) Accessory mental foramen: a rare anatomical finding. BMJ Case Reports. doi:10.1136/bcr.09.2010.3326
10. de Oliveira-Santos C, Couto Souza PH, de Azambuja Berti-Couto S, Stinkens L, Moyaert K, Fisher Rubira-Bullen I, Jacobs R (2012) Assessment of variations of the mandibular canal through cone beam computed tomography. Clin Oral Invest 16:387–393
11. Mizbah K, gerlach N, Maal TJ (2012) The clinical relevance of bifid and trifid mandibular canals. Oral Maxillofac Surg 16:147–151
12. Sachis JM, Peñarrocha M, Soler F (2003) Bifid mandibular canal. J Oral Maxillofac Surg 61:422–424
13. Kim ST, Hu K-S, Song W-C, Kang M-K, Park H-D, Kim H-J (2009) Location of the mandibular canal and the topography of its neurovascular structures. J Craniofac Surg 20:936–939
14. de Rodriguez Oliveira M, Júnior M, Santos Saud AL, Rodriguez Fonseca D, De-Ary-Pirez B, Ary Pires-Neto M, de Ary-Pires R (2011) Morphometrical analysis of the human mandibular canal: a CT investigation. Surg Radiol Anat 33:345–352
15. Liang X, Jacobs R, Corpas LS, Semal P, Lambrichts I (2009) Chronologic and geographical variability of neurovascular structures in the human mandible. For Sci Int 190:24–32
16. Kovisto T, Ahmad M, Bowles WR (2011) Proximity of the mandibular canal to the tooth apex. J Endod 37:311–315
17. Katakami K, Mishima A, Shiozaki K, Shimoda S, Hamada Y, Kobayashi K (2008) Characteristic of accessory mental foramina observed on limited cone-beam computed tomography images. J Endod 34:1441–1445
18. Balcioglu HU, Kocaelli H (2009) Accessory mental foramen. North Am J Med Sci 1:314–315
19. Ngeow WC, Dionysius DD, Ishak H, Nambiar P (2009) A radiographic study on the visualization of the anterior loop in dentate subjects of different age groups. J Oral Sci 51:231–237
20. Naitoh M, Hiraiwa Y, Aimiya H, Gotoh K, Ariji E (2009) Accessory mental foramen assessment using cone-beam computed tomography. Oral Surg Oral Med Oral Pathol Oral Radiol Endod 107:289–294
21. Devi KS, Shamila PB, Susan P (2011) Morphometrical and morphological study of mental foramen in dry dentulous mandibles of South Andhra population of India. Indian J Dent Res 22:542–546
22. Auluck A, Ahsan A, Pai KM, Shetty C (2005) Anatomical variations in developing mandibular nerve canal: a report of three cases. Neuroanatomy 4:28–30
23. Kim ST, Hu KS, Song WC, Kang MK, Park HD, Kim HJ (2009) Location of the mandibular canal and the topography of its neurovascular structures. J Craniofac Surg 20:936–939
24. Mraiwa N, Jacobs R, van Steenbergen D, Quireynen M (2003) Clinical assessment and surgical implications of anatomical challenges in the anterior mandible. Clin Impl Dent Rel Res 5:219–225
25. Neves FS, Torres MGG, Oliveira C, Campos PSF, Crusoé-Rebello I (2010) Lingual accessory mental foramen: a report of an extremely rare anatomical variation. J Oral Sci 52:501–503
26. Gahleitner A, Hofschnelder U, Tepper G, Pretterklieber M, Schick S, Zauza K, Watzek G (2001) Lingual vascular canals of the mandible: evaluation with dental CT. Radiology 220:186–189
27. Krasny A, Krasny N, Prescher A (2011) Study of inferior dental canal and its contents using high-resolution magnetic resonance imaging. Surg Radiol Anat. doi:10.1007/s00276-011-0910-y
28. Kaufman E, Serman NJ, Wang PD (2009) Bilateral mandibular accessory foramina and canals: a case report and review of the literature. Dentomaxillofac Rad 29:170–175
29. Yilmaz AB, Akgül N, Akgül HM, Dagistanli S, Cakur B (2003) Relationship between mandibular nutrient canals and hypertension. J Int Med Res 31:123–125
30. Krasny A, Krasny N, Prescher A (2012) Anatomical variations of neural canal structures of the mandible observed by 3-Tesla magnetic resonance imaging. J Comput Assist Tomogr 36:150–153
31. Przystánska A, Bruska M (2012) Anatomical classification of accessory foramina in human mandibles of adults, infants, and fetuses. Anat Sci Int 87:141–149
32. Fuakami K, Shiozaki K, Mashima A, Shimoda S, Hamada Y, Kobayashi K (2011) Detection of buccal perimandibular neurovascularisation associated with accessory foramina using limited cone-beam computed tomography and gross anatomy. Surg Radiol Anat 33:141–146

33. Sisman Y, Sahman H, Sekerci AE, Totmak TT, Aksu Y, Mavili E (2012) Detection and characterization of the mandibular accessory buccal foramen using CT. Dentomaxillofac Rad 41:558–563
34. Apostolakis D, Brown J (2011) The anterior loop of the inferior alveolar nerve: prevalence, measurement of its length and a recommendation for interforaminal implant installation based on cone beam CT imaging. Clin Oral Impl Res 0:1–9. doi:10.1111/j.1600-0501.2011.02261.x
35. Lew K, Townsend G (2006) Failure to obtain adequate anaesthesia associated with a bifid mandibular canal: a case report. Aust Dent J 51:86–90
36. Pogrel A, Dorfman D, Fallah H (2009) The anatomic structure of the inferior alveolar neurovascular bundle in the third molar region. J Oral Maxillofac Surg 67:2452–2454
37. Jacobs R, Lambrichts I, Liang X, Martens W, Mraiwa N, Adriaensens P, Gelan J (2007) Neurovascularization of the anterior jaw bones revisited using high-resolution magnetic resonance imaging. Oral Surg Oral Med Oral Pathol Oral Radiol Endod 103:683–693
38. Liang X, Jacobs R, Lambrichts I, Vandewalle G (2007) Lingual foramina on the mandibular midline revisited: a macroanatomical study. Clin Anat 20:246–251
39. Wang PD, Serman NJ, Kaufman E (2001) Continuous radiographic visualization of the mandibular nutrient canals. Dentomaxillofac Rad 30:131–132
40. Scarfe WC, Farman AG, Sukovic P (2006) Clinical applications of cone-beam computed tomography in dental practice. J Can Dent Assoc 72:75–80
41. Desantis JL, Liebow C (1996) For common mandibular nerve anomalies that lead to local anaesthesia failures. JADA 127:1081–1086
42. Stein P, Brueckner J, Milliner M (2007) Sensory innervation of mandibular teeth by the nerve to the mylohyoid: implications in local anaesthesia. Clin Anat 20:591–595
43. Blanton PL, Jeske AH (2003) The key to profound local anaesthesia. Neuroanatomy JADA 134:753–760
44. Blanton PL, Jeske AH (2003) Dental local anesthetics Alternative delivery methods. JADA 134:228–234
45. Orhan K, Aksoy S, Bilecenoglu B, Sakul BU, Paksoy CS (2010) Evaluation of bifid mandibular canals with cone beam computed tomography in a Turkish adult population: a retrospective study. Surg Radiol Anat. doi:10.1007/s00276-010-0761-y
46. Aps JKM (2009) (2009) L'anesthésie locale de la mandibule et ses problèmes spécifiques. Le Fil Dentaire 43:14–16
47. Meechan JG (1999) How to overcome failed local anaesthesia. Br Dent J 186:15–20
48. Wong JK (2001) Adjuncts to local anesthesia: separating fact from fiction. JCDA 67:391–397
49. Blanton PL, Jeske AH (2003) Avoiding complications in local anesthesia induction. JADA 134:888–893
50. Liang X, Jacobs R, Lambrichts I, Vandewalle G, van Oostveld D, Schepers E, Adriaensens P, Gelan J (2005) Microanatomical and histological assessment of the content of superior genial spinal foramen and its bony canal. Dentomaxillofac Radiol 34(6):362–368
51. Boronat López A, Peñarrocha Diago M (2006) Failure of locoregional anesthesia in dental practice. Review of the literature. Med Oral Patol Oral Cir Bucal 11:e510–e513
52. Przystanska A, Bruska M (2005) Foramina on the internal aspect of the alveolar part of the mandible. Folia Morphol (Warsz) 64:89–91
53. Przynstanska A, Malgorzata B (2010) Accessory mandibular foramina: histological and immunohistochemical studies of their contents. Arch Oral Biol 55:77–80
54. Simmons MS, Oleson TD (1993) Auricular electrical stimulation and dental pain threshold. Anesth Prog 40:14–19
55. Dobreva D, Lalabonova H, Kirova D (2005) Electroacupuncture analgesia in oral surgery. J of IMAB-Annual Proceeding 2:20–21